The Triological Society
UPHOLDING THE NOBLE LEGACY

Premiere Publications from The Triological Society

Read all three of our prestigious publications, each offering high-quality content to keep you informed with the latest developments in the field.

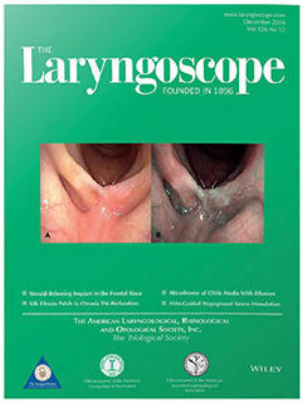

THE Laryngoscope
FOUNDED IN 1896

Editor-in-Chief: Samuel H. Selesnick, MD, FACS

The leading source for information in head and neck disorders.

Laryngoscope.com



Laryngoscope Investigative Otolaryngology
Open Access

Editor-in-Chief: D. Bradley Welling, MD, PhD, FACS

Rapid dissemination of the science and practice of otolaryngology-head and neck surgery.

InvestigativeOto.com



ENTtoday
A publication of the Triological Society

Editor-in-Chief: Alexander Chiu, MD

Must-have timely information that Otolaryngologist-head and neck surgeons can use in daily practice.

Enttoday.org

WILEY

Check for updates

The Laryngoscope
© 2021 The American Laryngological,
Rhinological and Otological Society, Inc.

MRI Study of Jellyfish Collagen, Hyaluronic Acid, and Cadaveric Dermis for Injection Laryngoplasty

Serban San-Marina, PhD; Andrew J. Bowen, MD, MSc; Michael S. Oldenburg, MD; Stephen G. Voss, MS; Danielle E. Hunter, BSc; Slobodan Macura, PhD; Ryan Meloche, BSc; Alen Lee Miller II PhD; Andrew Mearns Spragg, PhD; Dale C. Ekbom, MD

Abstract

Objectives/Hypothesis: Test a new jellyfish collagen biomaterial aimed to increase duration of injection medialization laryngoplasty (IL) against two products in clinical practice.

Study Design: Animal model.

Methods: Left recurrent laryngeal nerve sectioning and IL were performed in New Zealand White rabbits (N = 6/group). Group 1 received micronized cross-linked jellyfish collagen (MX-JC) and adipose derived stem cells (ADSCs), Group 2, MX-JC alone, Group 3, cross-linked hyaluronic acid (X-HA), and Group 4, micronized acellular dermis (MACD). Animals were sacrificed at 4 and 12 weeks. Major outcomes were MRI tissue volumes and histopathology.

Results: After 100 μL IL MRI volumes (means ± STD) at 4 and 12 weeks were: Group 1: 27.2 ± 15.6 and 13.1 ± 5.2 μL, Group 2: 60.8 ± 18 and 27.8 ± 2.47 μL, Group 3: 27.4 ± 12 and 10.6 ± 8 μL, and Group 4: 37.5 ± 11 and 9.85 ± 1 μL. Group 2 volumes were largest and Group 3 were smallest in all comparisons ($P < .05$). Histologically, low grade inflammatory responses were observed in Group 1, mild histiocytic infiltration in Group 2, widespread muscle fiber loss in Group 3, and plasmocytic infiltration in Group 4.

Conclusions: MX-JC showed the least resorption at 4 and 12 weeks among all groups. T cell inflammatory responses were observed with MX-JC but were reduced by 12 weeks while B cell immune responses, indicative of antibody priming, were predominantly noted with MACD. MX-JC + ADSC showed low grade immunity while the XHA showed greater myocyte loss compared to the other groups.

Key Words: Injection laryngoplasty, stem cells, micronized acellular dermis, Cymetra®, Restylane®, Jellyfish collagen, plasmocytic immunity, T-cell response.

Level of Evidence: NA

***Laryngoscope*, 00:1–9, 2021**

Abbreviations

ADSC	adipose mesenchymal stem cells
BSE	bovine spongiform encephalopathy
IL	injection (medialization) laryngoplasty
JC	jellyfish collagen
MACD	micronized acellular dermis
MRI	magnetic resonance imaging
MX-JC	micronized crosslinked jellyfish collagen
NMR	nuclear magnetic resonance
RLN	recurrent laryngeal nerve
UVFP	unilateral vocal fold paralysis
VF	focal fold
XL-HA	crosslinked hyaluronic acid

From the Mayo Clinic ENT (S.S.-M., A.J.B., M.S.O., S.G.V., D.E.H., D.C.E.), Rochester, Minnesota, U.S.A.; Department of Biochemistry and Molecular Biology & Metabolomics Core (S.M., R.M.), Mayo Clinic, Rochester, Minnesota, U.S.A.; Tissue Engineering and Sarcoma Biology Laboratory (A.L.M.), Mayo Clinic, Rochester, Minnesota, U.S.A.; and the Jellagen Pty Ltd. (A.M.S.), Cardiff, United Kingdom.

Additional supporting information may be found in the online version of this article.

Editor's Note: This Manuscript was accepted for publication on February 3 2021.

Send correspondence to Serban San-Marina, PhD, Mayo Clinic ENT, 200 1st St SW, Rochester, MN 55902. E-mail: ssanmarina@gmail.com

DOI: 10.1002/lary.29501

INTRODUCTION

Unilateral true vocal VF paralysis (UVFP) is a condition that disrupts voice communication and glottal competence and has a multifactorial etiology, primarily caused by thyroid and non-thyroid surgery, malignancy, and idiopathic causes. Thyroidectomy is a major risk factor accounting for 12% to 17% of cases.[1] Injection medialization laryngoplasty (IL) is a temporary, first line treatment for UVFP. Typically, a volume-augmenting material is injected into the paraglottic space of the paralyzed VF aiming to bring it to the midline. Even though a variety of biomaterials and protocols have been described[2,3], interest revolves around compounds that can be delivered with smaller bore needles under local anesthesia, are well tolerated, and do not migrate.[4] Each biomaterial aims to achieve an optimal balance between ease of injection, duration of laryngeal closure, and degree of restored phonation. Three compounds have gained prominence: calcium hydroxyl-apatite and its carboxymethyl cellulose carrier (Radiesse®), cross-linked hyaluronic acid (Restylane®), and human cadaveric micronized acellular dermis (Cymetra®). As novel

materials such as silk[5] and tissue-mimetic nano-fibrillar hybrids[6] are being developed, a more personalized approach to IL may become possible.

Several studies, including ours, have demonstrated the benefit of adipose mesenchymal stem cells (ADSCs) used by themselves or co-injected with scaffolding biomaterials and growth factors.[7,8] In previous work we showed greater medialization by ADSCs co-injected with Cymetra compared to Cymetra alone.[8,9] Recently Cymetra was phased out due to new FDA minimal manipulation requirements. Given that collagen is the main component of Cymetra, this presented an opportunity to test a new biomaterial composed of high purity collagen.

Collagen provides appropriate signals for new tissue formation[20] and is one of the most used material for tissue engineering. Jellyfish collagen has proven biocompatibility, biodegradability, low immunogenicity, and cell-adhesive properties.[19] Jellagen® collagen is extracted from *Rhizostoma pulmo* "" (the "barrel jellyfish"), a Cnidaria variety from the Rhizostomatidae family that grows abundantly off the coast of Western Wales, UK. It is actively harvested and processed for medical applications.[10] The highly purified product consists of "archaic-type" collagen with a preponderance of type I-collagen, the preferred collagen type for 3D tissue culture sponges.[11,12]

To make an initial determination of the potential benefit of jellyfish collagen we compared micronized crosslinked Jellagen (MX-JC), MX-JC+ ADSCs, Cymetra (micronized acellular dermis, MACD), and Restylane (crosslinked hyaluronic acid, X-HA) using our previously described rabbit IL model.[8,9]

METHODS

Animals

Following Institutional Animal Care and Use Committee (IACUC) approval (IACUC A4201), 24 three-week-old female New Zealand White rabbits of average weight 3.12 ± 0.18 kg were divided into four groups of N = 6 based on power calculations from previous data.[8] After 2 weeks for acclimatization, surgery for RLN sectioning and fat collection was performed with intramuscular ketamine 42 mg/kg, xylazine 6 mg/kg, and acepromazine 1.2 mg/kg for anesthesia induction and 1% - 2% isoflurane for maintenance. Buprenorphine 0.18 mg/kg and carprofen 1.5 mg/kg were used for postoperative pain. The left RLN was located by blunt dissection along the inferior thyroid artery and a 1-cm section of the nerve was removed (Fig. 1A). A piece of fat approximately 1.5 cm in diameter was collected from all rabbits from the cricotracheal area and placed in sterile saline solution. Only fat from Group 1 was processed for ADSC expansion and injection. Two weeks later animals were re-anesthetized, the larynx exposed, and IL injection was performed with a 23-gauge needle and visualized by image guided endoscopy (Fig. 1B). Injected biomaterials were aimed lateral to the vocal process of the arytenoid cartilage, injected in 100 μL volumes, over a 2 min span, with a 1-mL syringe. XL-JC (Jellagen brand, 225 mg/mL, average size 300 nm and 1% EDC cross-linking) was reconstituted from dry powder with pH-buffered saline at the time of injection and warmed up to 37°C to facilitate mixing. In Group 1, the material was mixed with $1X10^6$ ADSCs and 5 ng/mL of TGF-β2 just prior to injection and delivered into the same animal from which ADSCs were harvested. MACD (Cymetra brand, 275 mg/mL) and XL-HA (Restylane brand, 20 mg/mL) were injected according to the manufacturers' specifications. Contemporaneous notes and videos were kept documenting the extent of RLN paralysis, needle location, net injected volume, and complications during surgery or post-op recovery. Injections that delivered 100 μL into the left paraglottic space were scored as "high confidence", all others as "medium confidence". To monitor overall health, animals were weighed at arrival, after surgery, and once a week thereafter.

Preparation of Rabbit Mesenchymal Stem Cells

Preparation of rabbit ADSCs was previously described.[8] Briefly, adipose tissue was minced with scalpels and digested with 3 to 5 mL of 0.15% collagenase type 1 solution (C0130-1G; Sigma, St. Louis, MO) in Advanced MEM media (A-MEM, Life Sciences) containing 10% fetal bovine serum (FBS), 1% GlutaMAX, and 1 mg/mL penicillin/streptomycin solution. Cells were separated from the fat layer by occasional shaking at 37°C for 1.5 hours. Followed by centrifugation at 500*g* for 5 minutes. The pellet was washed with phosphate-buffered saline, strained through a 70 μm sieve to remove large particulate matter, reconstituted by centrifugation for 5 minutes at 500*g*, and finally resuspended in 5 to 10 mL of A-MEM media overnight at 37°C, in 5% CO_2, and 95% humidity atmosphere. The following day, nonadherent material was removed, and fresh media added. Media changes were every 2 to 3 days. Cells were passaged 1:2 at 60% to 80% confluence. Passage 3 cells were cryopreserved and freshly expanded for 24 to 48 hours. Before IL. A total of 1×10^6 ADSCs were co-injected with MX-JC in Group 1 rabbits only.

Viscosity and Rheology

Rheological properties of the three compounds were evaluated using a DHR-1 Discovery Hybrid Rheometer (TA Instruments, New Castle, DE, USA) equipped with a 40 mm parallel Peltier plate geometry. Dynamic viscoelasticity was measured as a function of frequency in the linear viscoelastic region using 1.0 mL of sample. Test temperature was 39°C, soak time 0 s, shear rate 0.1 to 500 s^{-1}, max equilibration time 60 s and, and sampling period 30 s.

MRI

NMR experiments were performed using an Avance III 300 MHz (7 Tesla) wide bore NMR spectrometer equipped with micro-imaging accessories (Bruker, BioSpin, Billerica, MA) and a 20 mm diameter volume coil. Specimens were gently dried with tissue paper, transferred into 20 mm tubes, and tightly secured in the middle of the tube with a custom-made Teflon holder. Tubes were filled with Fluorinert FC-770 (3 M, St. Paul, MN), to improve the field homogeneity around the specimen without adding background noise. Images were acquired at 21°C to 25°C. The RARE (Rapid Acquisition with Refocused Echoes) sequence in multi-slice (2D) and volume (3D) mode was used, with the following parameters: Repetition time: 4000 ms, Echo time: 10.37 ms, RARE factors: 12, FOV: 16 cm × 16 cm, Matrix: 160 × 160, 1) Slice Thickness: 0.5 mm, 2) In Plane Resolution: 100 μm/pxl, 3) Slice Thickness: 0.5 mm, and Acquisition time: 10 m 24 s. A slice and 3D protocol were compared for maximum feature resolution. A multi-slice image collection was recorded for every specimen and 3D for a few representative specimens. The multi-slice protocol consisted of 26, 0.5 mm digital "sections" of the larynx starting from the cricothyroid cartilage and moving in a superior direction. To identify start and end location of the medialization material an initial short scan (3–5 slices) was performed after which a "digital box" containing the bulking

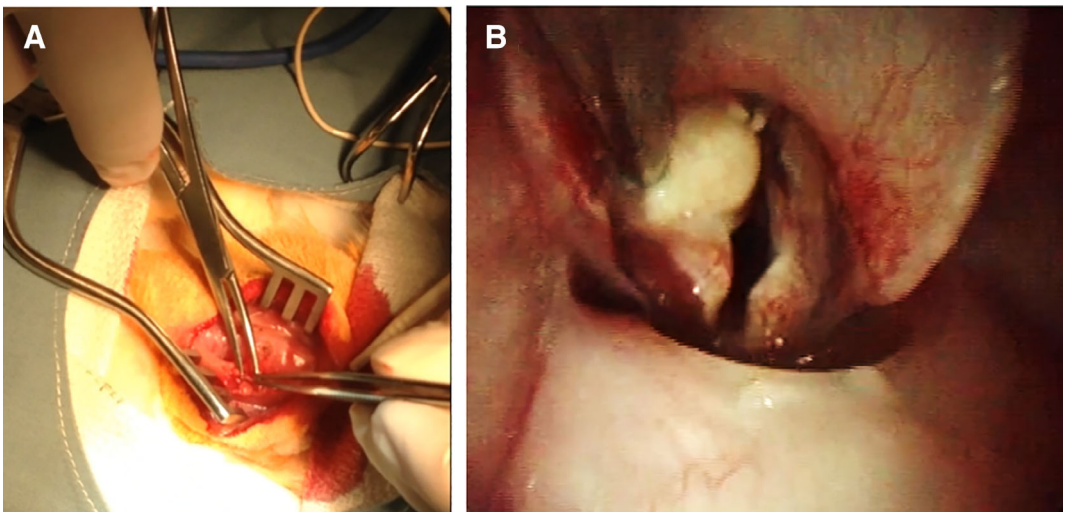

Fig 1. Surgical protocols. (A) RLN dissection and neurotomy. (B) Injection medialization laryngoplasty (IL) using Cymetra® (white matter) delivered through a 23 g IL needle. [Color figure can be viewed in the online issue, which is available at www.laryngoscope.com.]

material was constructed and sliced as above. With the 3D protocol acquired overnight (tt 11 hours) the following parameters were used: TR 2500, TE 10 ms, TEeff 30, RARE factor 8, FOV 16 mm × 20.48 mm × 25.6 mm, Matrix 256 × 320 × 400, NAV 1 with isotropic resolution of 64 μm/pixel. In total, 26 MRI images of the larynx with "slice" thickness of 0.5 mm and no gaps between slices were recorded for each animal, starting at the cricoid landmark and moving in a superior direction. Images depict medialization ellipsoids caused by the injected materials as well as non-injected tissue. MRI images depict size and position of the largest ellipsoid for each animal sacrificed at 4 and 12 weeks. Slice volumes (μL) for each animal were ordered from highest to lowest rather than in the order of sectioning.

Histology

Fixed tissues were embedded in paraffin and 5 μm sections were cut and stained with hematoxylin and eosin as previously described.[9,13] Briefly, slides were deparaffinized and stained in Harris hematoxylin solution for10 minutes then rinsed 5 minutes in running tap water. After 1–5 sec. differentiation in I% acid alcohol and 1 minutes rinse with tap water, bluing was performed for 3 minutes in 0.2% ammonia water or saturated lithium carbonate solution. Following a 5 minutes rinse in tap water slides and 10 dips in 95% alcohol, specimens were counterstained in eosin solution for 1 minutes and then dehydrated with one change of 95% ethanol, and two, 5 minutes changes of 100% alcohol. Finally, specimens were mounted with xylene media. Slides were analyzed in a nonblinded manner, consistent with the recommendations of the National Toxicology Position Statement on Informed ("Nonblinded") Analysis[14] by a board-certified veterinary pathologist (N.M.G., DVM, MS, MRCVS, CPIA, CMAR, Diplomate ACLAM & ACVP), in the Department of Comparative Medicine, Mayo Clinic Arizona (pathology report attached as Supporting Information).

Volumetry

MRI IL volumes were measured with imaging software (Analyze, Mayo Clinic, or ImageJ https://imagej.nih.gov/ij/) by summing areas of semiautomatic segmentation in different slices and multiplying the total area by the slice thickness.

Statistical Analysis

Group size for 80% statistical power and $P \leq .05$ was calculated according to Lehr[15]:

$$N = 16\frac{s^2}{d^2}$$

where s is the standard deviation and d the difference between population means based on previous findings.[8,9] To help limit observational bias, all digital "slices were separately scored for volume by three independent observers. Ellipsoids were confirmed by histology. To determine statistical differences between groups, ellipsoid volumes were ordered according to size and ranked. Kruskal-Wallis ANOVA of group ranks was performed with $P \leq .05$ threshold for statistical significance. Individual group differences were compared with Mann–Whitney U test and statistical significance were assigned at $P \leq .05$.

RESULTS

Viscoelastic Testing

Various XL-JC concentrations were tested by rheology to predict in vivo behavior (Fig. 2A). We observed a concentration-dependent trend toward decreased viscosity as shear rates increased (Fig. 2B). Deformation curves for MACD and XL-JC ran almost in parallel, while XL-HA showed the highest resistance to thinning (Fig. 2C). All biomaterials displayed non-Newtonian, liquid thinning behavior.

Animals

Animal data are summarized in Table I. One animal in Group 4 died from anesthesia. No animals were lost due to surgical procedures, post-operatory care, or other complications. Experimental success rates were determined by analysis of videos and contemporaneous notes. For RLN surgery 21/23 animals (~91%) displayed paralysis of the left VF. One animal had partial VFP and one

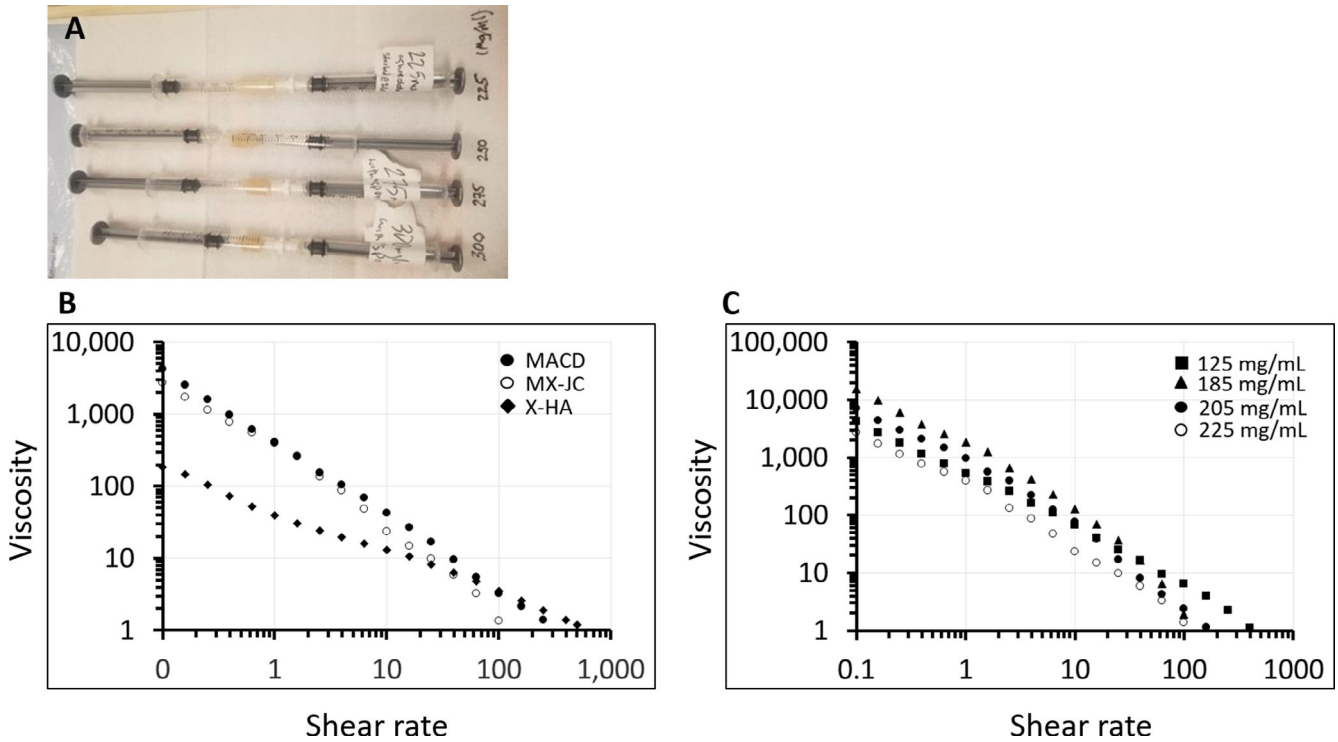

Fig 2. Rheological features of injected materials. (A) Interconnected syringe barrel assembly used for suspending MX-JC in phosphate-buffered saline. (B) Rheological features of MX-JC solutions showing non-Newtonian, liquid thinning behavior. (C) Comparison of rheological features for Cymetra® (275 mg/mL), MX-JC (225 mg/mL), and Restylane® (20 mg/mL). [Color figure can be viewed in the online issue, which is available at www.laryngoscope.com.]

had no VFP (Group 3). Approximately 70% of all injections were "high confidence." Volumes exceeding 100 μL and material extrusion and/or deviation from the delivery site accounted for, respectively, 22% and 8% of "medium confidence" injections. Because of the difficulty of co-injecting ADSCs with MX-JC, five animals in Group 1 (83%) were scored as "medium confidence." Rabbits fed normally, and weight gain was comparable across groups (not shown).

MRI Analysis

Forty-six percent of MRI images at 4 weeks and 29% at 12 weeks reveal injected material. This ~37% decrease (P = .002) is likely due to resorption over time. Resorption rates were different for each material (see Table I and volume data calculation below). Highest resorption rate was in Group 3 (58%), followed by Group 4 (47%), Group 1 (31%), and lastly Group 2 (29%). MRI data for animals sacrificed at 4 weeks are shown in Figure 3 and at 12 weeks in Figure 4. When 4 and 12 weeks data are collapsed the volume of material (mean ± SD) remaining after IL was: Group 1, 2.72 ± 1.0 μL, Group 2, 4.06 ± 2.0 μL, Group 3, 1.88 ± 1.0 μL, and Group 4, 2.49 ± 1.0 μL. The Group 2 mean volume was statistically significantly higher than Groups 1, 3 and 4 (P < .0009).Rank data at 4 and 12 weeks after IL are shown in Figure 5. Group 2 ellipsoid volumes were consistently larger than the three remaining groups.

Histology

Representative histology data are shown in Figure 6 and summarized in Table I. The complete histology report is attached as Supporting Information. MX-JC stained as a reticular, well-defined material surrounded by a layer of inflammatory cells. This was most apparent in Group 2 at 4 weeks post IL. By week 12, the inflammatory response had significantly subsided. By contrast, when co-injected with ADSCs, MX-JC (Group 1) was relatively free of inflammatory cells. XL-HA appeared as a bluish crystal-like material relatively free of surrounding inflammatory cells as previously reported.[16] It was easily distinguished at 4 weeks but appeared less defined at 12 weeks, likely due to resorption. MACD was similar in appearance to XL-JC, with a well-defined nodular shape that was easily visible at both 4 and 12 weeks. Results are summarized in Table I. First, some degree of muscle atrophy, likely secondary to VF denervation was observed in all groups. Second, adipocyte infiltration was observed in all groups and not just in Group 1, but it was not possible to distinguish injected ADSCs from proliferating local tissue adipocytes. Third, in the case of Group 3, there was widespread myocytic death and fibroplasia associated with XL-HA injections. And fourth, two distinct types of inflammatory nodules were noted with JMX-JC and MACD, namely a histiocytic T cell inflammatory infiltration for the former and a plasmocytic B cell immune response for the latter.

Table I.
Summary of Animal Data.

	Rabbits			Procedure				Histology		
				VFP IL ADSC	μL Injected	Sacrifice Week	MRI μL Volume	Val	Features	Complications
Group 1	1	++	+	10^6	100	4	9.3	+	ma	Seroma-drained
	2	++	+	10^6	120	4	34.5	++	hn	—
	3	++	+	10^6	120	4	37.8	++	a, hn	—
	4	++	++	10^6	100	12	16.8	+	ma	—
	5	++	+	10^6	170	12	7.1	+	a	Seroma
	6	++	+	10^6	150	12	15.3	+	a, ln	—
Group 2	7	++	++	—	100	4	73.5	++	hn	—
	8	++	++	—	100	4	40.9	++	hn	—
	9	++	++	—	100	4	68.0	++	hn	—
	10	++	+	—	100	12	1.7	−−	a, ma	Seroma-drained
	11	++	++	—	100	12	26.0	++	hn	—
	12	++	++	—	100	12	29.5	++	a, hn	—
Group 3	13	++	++	—	100	4	29.5	++	md/f	—
	14	+	++	—	100	4	14.9	++	a, md/f	Wound dehiscence
	15	++	+	—	110	4	37.7	++	a, md/f	—
	16	++	++	—	100	12	5.0	+	md/f	—
	17	−−	++	—	100	12	19.7	++	a, md/f	—
	18	++	++	—	100	12	7.0	+	a, md	—
Group 4	19	++	++	—	100	4	44.4	++	ln	—
	20	++	++	—	100	4	42.9	++	a, ln	—
	21	++	++	—	100	12	25.2	++	a, ln	
	22	++	++	—	100	12	10.4	++	ln	Seroma-drained
	23	++	++	—	100	12	9.3	++	ln	—
	24	−−	−−	—	—	—	—	−−	—	Died at anesthesia

++/+ = high/medium confidence; ADSC = adipose mesenchymal stem cells; IL = injection medialization laryngoplasty; Val = MRI validation; VFP = vocal fold paralysis. Histology Features: a = adipocytes infiltration; hn = histiocytic nodule; ln = lymphocytic nodule; ma = muscle atrophy; md/f = myocyte death/fibroplasia.

DISCUSSION

Here we describe a new biomaterial for IL derived from jellyfish collagen (Jellagen MX-JC). The principal findings of the study are: 1) MX-JC had longer residence in the thyroarytenoid space than XL-HA and MACD, 2) MX-JC + ADSCs medialization volumes were smaller than with MX-JC alone, and 3) MX-JC and MACD engendered two different immune responses, mediated by T and B cells, respectively, while XL-HA was associated with increased incidence of myocytic loss (Table I). Our rabbit model was designed to reflect the clinical presentation of patients undergoing IL. First, we induced UVFP by RLN sectioning to account for tissue responses associated with denervation. Models that do not recreate UVFP do not consider myocytic loss and fat cell infiltration observed in this study. Second, we use high-definition (7 Tesla) MRI and imaging software for precise measurements of ellipsoid volumes thus enabling meaningful ANOVA, t- and rank test analyses, yielding highly statistically significant group differences. And third, we monitor confidence in the protocol by detailed contemporaneous notes, video recording, and histopathology.

The use of 7 T MRI to visualize residence time of IL materials was previously reported.[16] Using a canine IL model, these authors find 86% of Restylane present at the injection site at 8 weeks post-IL. By contrast, carboxymethylcellulose (Prolaryn® gel) was widely dispersed, with little material left at 8 weeks.[16] We found that at 12 weeks post-IL only approximately 42% of Restylane could be detected in our rabbit model. These differences may be related to variations in experimental design between our study and,[16] pertaining to species (rabbit v. canine), surgery (denervation v. no denervation), IL protocol (single v. bi-lateral vocal fold injections), and observation times (12 weeks v. 8 weeks). In our study, loss and atrophy of intrinsic laryngeal myofibers with replacement by clear space were observed in the Restylane group (Supporting Information). This suggests that tissue loss may have facilitated its migration away from the injection site. Presence of macrophages and histiocytes in the absence of a lymphoplasmacytic reaction was found in both studies, for Prolaryn in[16] and Jellagen MX-JC in ours.".

Our study is limited both in scope and duration, as we do not address phonation issues[17,18] and report relatively short IL observations. These limitations will be addressed in future experiments using an optimized jelly fish material that is currently being developed.

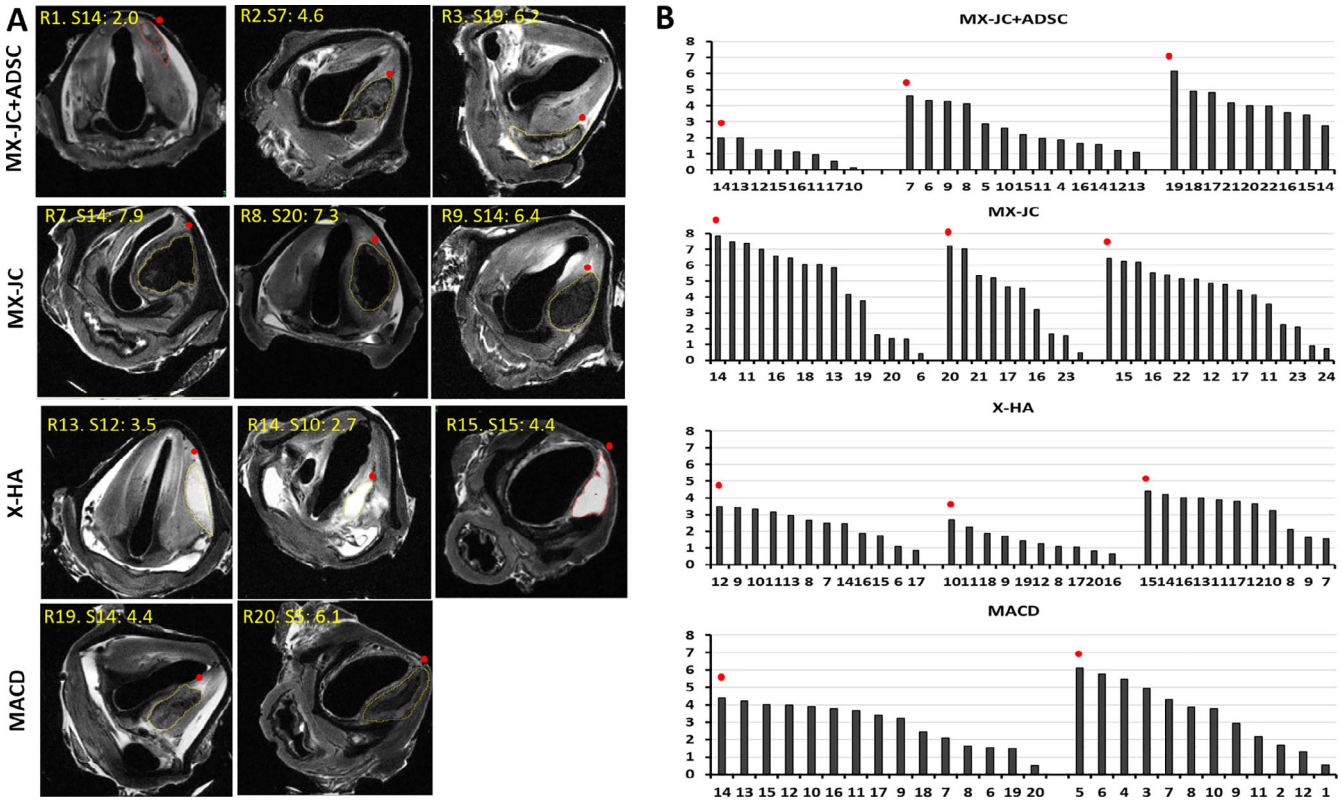

Fig 3. MRI images and volume calculations at 4 weeks post IL. (A) MRI images corresponding to the largest IL ellipsoids for each of the 11 animals are depicted and identified by a red dot. Text in yellow denotes Rabbit No. (R), digital Slice No. (S), and IL volume (μL). (B) IL ellipsoid volumes depicted from largest to smallest. Red dots correspond to the ellipsoids showed in A. X-axis, slice number, y-axis, microliters. [Color figure can be viewed in the online issue, which is available at www.laryngoscope.com.]

Cymetra and Restylane are leading IL products but their benefits are short lived. Less frequently used are bovine gelatin (Gelfoam®), carboxymethylcellulose with or without calcium-hydroxlyapatite (Prolaryn and Prolaryn Plus®), bovine collagen (Zyplast® and Zyderm®), fat, and fascia, to name just a few. Cymetra, which is prepared from human cadaver skin, has batch to batch variability issues (DCE, personal communication) that may impact its IL benefit. By contrast, medical grade Jellagen XL-JC is a new type of medical collagen with controlled batch reproducibility and optimal type B collagen fibers that support tissue regeneration.[11] In preliminary experiments Jellagen XL-JC showed no cytotoxicity against rabbit ADSCs and human mesenchymal cells (not shown). Furthermore, Jellagen XL-JC injected under the skin of mice and rats produced no overt toxicity.[10] A working concentration of 225 mg/mL produced a tactile response similar to MACD (Cymetra brand, 275 mg/ml) and allowed acceptable delivery control (see below). Rheology analysis confirmed that MX-JC and MACD have similar liquid-thinning properties, but MX-JC displayed a compression effect that caused the material to unexpectedly eject as pressure built up under the plunger. As ADSCs contributed additional viscosity, MX-JC + ADSCs injections had a preponderance of "medium-low confidence" evaluationsSelf-grafted ADSCs are of considerable interest for IL. A recent study demonstrates the safety and efficacy of adipose-enriched fat grafts for glottal gap defects.[7] Our group also reported that ADSCs co-injected with MACD produced greater medialization volumes at 4 and 12 weeks after IL[8] than MACD alone. A follow-up study found that histone variants H3.3, H2A.V, and H2A.Z that are associated with open chromatin states and ADSC proliferation were overrepresented in the MACD + ADSC group relative to structural histones.[13]

In the present study, ADSCs co-injected with MX-JC did not boost medialization volumes relative to MX-JC alone. ADSCs, with well-described immunosuppressive effects, appeared to dampen the T cell-mediated immune response to MX-JC, characterized by dendritic cells and macrophage infiltration, which may explain this observation (Table I and Figure 6). By contrast, a similar dampening effect of ADSCs on the lymphocytic inflammatory response to MACD was not observed.[9] These two types of inflammatory responses, B-cell for MACD and T-cell for MX-JC may reflect differences in particle size (MX-JC particles were 1.5–2.0 larger than MACD particles) or other biomaterial properties. Alternatively, jellyfish collagen may not be efficiently degraded in the rabbit. Further experiments are currently underway to identify the immune mechanisms associated with these two inflammatory responses.

Increasing incidence of UVFP, due to higher surgery volumes and an aging population, highlights a growing

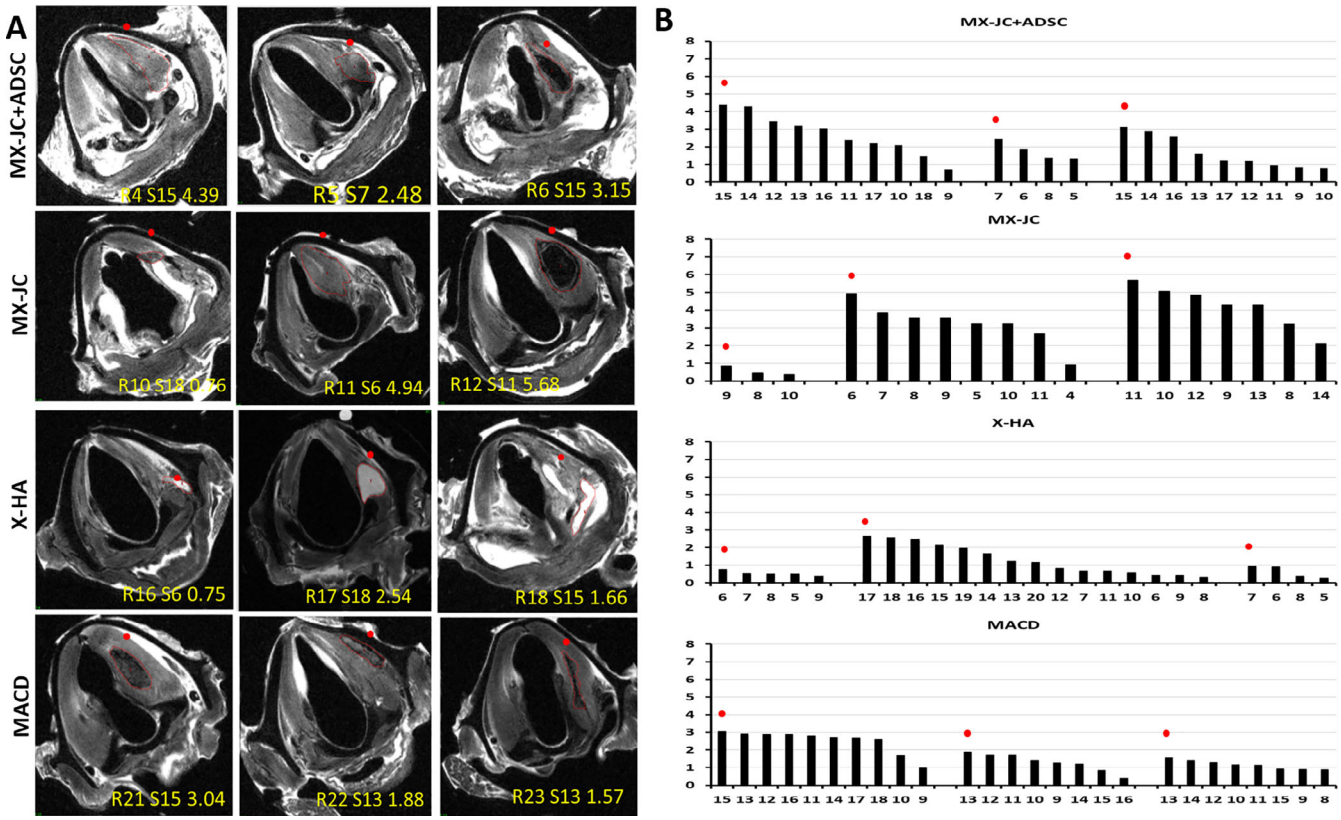

Fig 4. MRI images and volume calculations at 12 weeks post IL. (A) MRI images corresponding to the largest IL ellipsoid for each of the 12 animals. (B) IL ellipsoid volumes. See Figure 3 captions for details. [Color figure can be viewed in the online issue, which is available at www.laryngoscope.com.]

need for IL biomaterials that can be delivered within the confines of a clinical practice, under local anesthesia, are well tolerated, and do not migrate. Because initial attempts at a permanent IL solution using Teflon resulted in granuloma, the focus has shifted to absorbable materials, such as MACD, autologous fat, hyaluronic acid, collagen, and others that are less prone to granuloma.[19,20] These efforts have sought to enhance materials already in use, for example by adding ADSCs, or discover novel biomaterials.[2–4,7,19,20] Jellagen MX-JC is a new and uniquely biomimetic material obtained from an ancient marine organism.[21] It can be produced under ISO standards that eliminate batch to batch manufacturing variability, is amenable to crosslinking, electrospinning, and sponge gels for spheroid culture, and has shown promise for tissue regeneration and wound healing.[22–24] Notably, Jellagen MX-JC upregulates several tissue regeneration biomarkers and suppresses production of toxic cytokines (manuscript in preparation). In the present study, we compared Jellagen MX-JC, Cymetra MACD, and

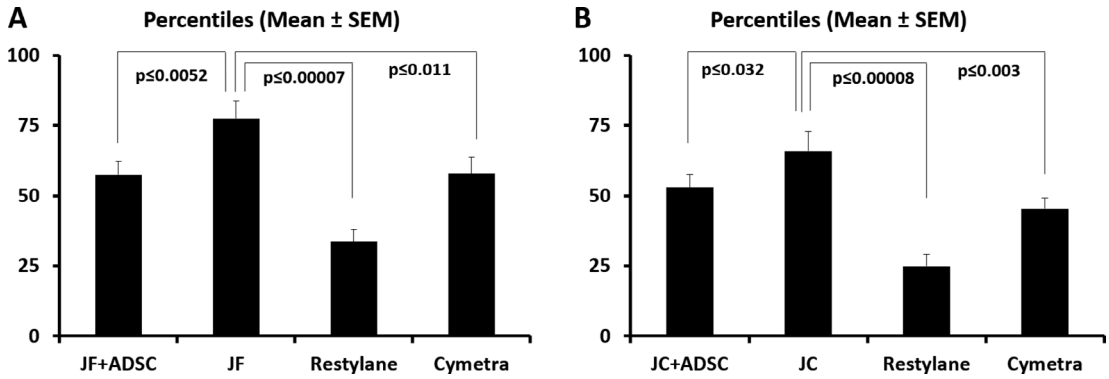

Fig 5. Rank analysis of ellipsoid volumes at (A) 4- and (B) 12-weeks after IL. Ellipsoid volumes were ordered from high to low and ranked on a 100 to 1 scale. Rank data were extracted for each group and statistical significance was determined using Kruskal-Wallis H-test ($P < .001$). Individual groups differences were compared by the Mann–Whitney U test.

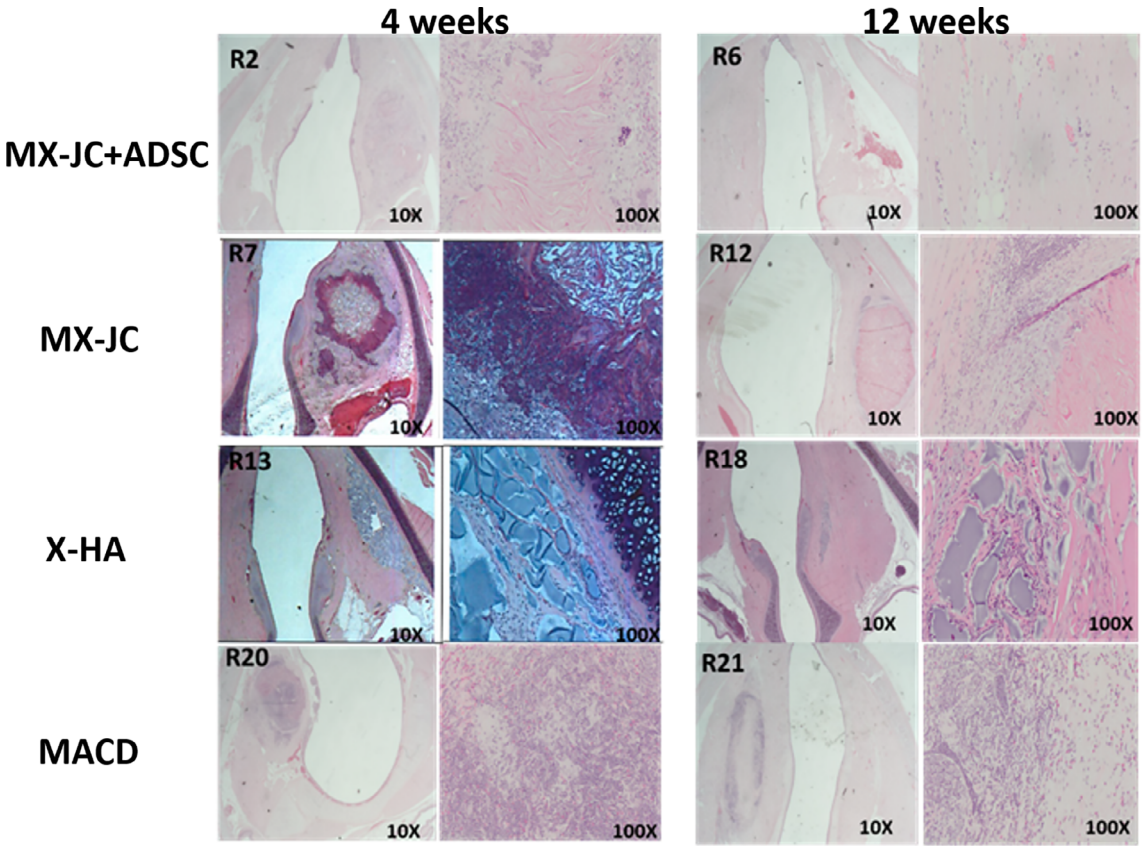

Fig 6. Histology analysis of tissue sections. Representative slides from each group at 4- and 12-weeks after IL are shown using 10× and 100× magnification. Note right side depiction of ellipsoids for R2, R6, R7, R12, R13, and R18, and left side ellipsoid depictions for R20 and R21. R# = rabbit number. [Color figure can be viewed in the online issue, which is available at www.laryngoscope.com.]

Restylane X-HA tissue retention at 4- and 12-weeks post IL and provided an initial histopathology assessment. We find that Jellagen MX-JC has longer residence time with no overt toxicity when compared to these predicate biomaterials. This promising initial assessment supports further investigation of Jellagen MX-JC for IL.

CONCLUSION

Using high resolution MRI at 4- and 12-weeks post IL, we found that MX-JC medialization volumes were 40% and 100% greater compared to MACD and XL-HA, respectively. This may be related to the inability of rabbit tissue to process jellyfish collagen and/or to inflammatory/immune response related to particle size that decreases resorption of Jellagen MX-JC. The study did not address tissue regeneration, but such effects cannot be ruled out. No overt adverse reactions were noted with MX-JC and MACD, whereas X-HA injections were associated with higher frequency of myocytic loss.

ACKNOWLEDGMENTS

Funds for the project were provided in part by Jellagen Pty Ltd. under a work agreement with the Mayo Clinic, with SSM and DCE as Principal IACUC Investigators.

CONFLICT OF INTEREST

The study authors declare no competing financial interests. SSM is a member of the Scientific Advisory Board for Jellagen Pty Ltd.

BIBLIOGRAPHY

1. Spataro EA, Grindler DJ, Paniello RC. Etiology and time to presentation of unilateral vocal fold paralysis. *Otolaryngol Head Neck Surg* 2014;151: 286–293.
2. Li L, Stiadle JM, Lau HK, et al. Tissue engineering-based therapeutic strategies for vocal fold repair and regeneration. *Biomaterials* 2016;108: 91–110.
3. Mallur PS, Rosen CA. Vocal fold injection: review of indications, techniques, and materials for augmentation. *Clin Exp Otorhinolaryngol* 2010;3: 177–182.
4. Eppley BL, Dadvand B. Injectable soft-tissue fillers: clinical overview. *Plast Reconstr Surg* 2006;118:98e–106e.
5. Gulka CP, Brown JE, JEM G, et al. A novel silk-based vocal fold augmentation material: 6-month evaluation in a canine model. *Laryngoscope* 2019; 129:1856–1862.
6. Latifi N, Asgari M, Vali H, Mongeau L. A tissue-mimetic nano-fibrillar hybrid injectable hydrogel for potential soft tissue engineering applications. *Sci Rep* 2018;8:1047.
7. Lasso JM, Poletti D, Scola B, Gomez-Vilda P, Garcia-Martin AI, Fernandez-Santos ME. Injection Laryngoplasty using autologous fat enriched with adipose-derived regenerative stem cells: a safe therapeutic option for the functional reconstruction of the glottal gap after unilateral vocal fold paralysis. *Stem Cells Int* 2018;2018:8917913.
8. Oldenburg MS, Ekbom DC, San Marina S, et al. Preliminary results of tissue-engineered injection laryngoplasty material in a rabbit model. *Laryngoscope* 2017;128:160–167.
9. Oldenburg MS, Janus J, Voss S, et al. Histologic evaluation of micronized AlloDerm after injection Laryngoplasty in a rabbit model. *Laryngoscope* 2017;127:E166–E169.

10. Widdowson JP, Picton AJ, Vince V, Wright CJ, Mearns-Spragg A. In vivo comparison of jellyfish and bovine collagen sponges as prototype medical devices. *J Biomed Mater Res B Appl Biomater* 2018;106: 1524–1533.
11. Chevallay B, Herbage D. Collagen-based biomaterials as 3D scaffold for cell cultures: applications for tissue engineering and gene therapy. *Med Biol Eng Comput* 2000;38:211–218.
12. Cheng X, Shao Z, Li C, Yu L, Raja MA, Liu C. Isolation, characterization and evaluation of collagen from jellyfish *Rhopilema esculentum* kishinouye for use in hemostatic application. *PLoS One* 2017;12: e0169731.
13. Voss S, San-Marina S, Oldenburg MS, et al. Histone variants as stem cell biomarkers for long-term injection medialization laryngoplasty. *Laryngoscope* 2018;128:E402–E408.
14. Sills RC, Cesta MF, Willson CJ, Brix AE, Berridge BR. National toxicology program position statement on informed ("nonblinded") analysis in toxicologic pathology evaluation. *Toxicol Pathol* 2019;47:887–890.
15. Lehr R. Sixteen S-squared over D-squared: a relation for crude sample size estimates. *Stat Med* 1992;11:1099–1102.
16. Zeitels SM, Lombardo PJ, Chaves JL, et al. Vocal fold injection of absorbable materials: a histologic analysis with clinical ramifications. *Ann Otol Rhinol Laryngol* 2019;128:71S–81S.
17. Caton T, Thibeault SL, Klemuk S, Smith ME. Viscoelasticity of hyaluronan and nonhyaluronan based vocal fold injectables: implications for mucosal versus muscle use. *Laryngoscope* 2007;117:516–521.
18. Klemuk SA, Titze IR. Viscoelastic properties of three vocal-fold injectable biomaterials at low audio frequencies. *Laryngoscope* 2004;114:1597–1603.
19. Hertegard S, Hallen L, Laurent C, et al. Cross-linked hyaluronan versus collagen for injection treatment of glottal insufficiency: 2-year follow-up. *Acta Otolaryngol* 2004;124:1208–1214.
20. McCulloch TM, Andrews BT, Hoffman HT, Graham SM, Karnell MP, Minnick C. Long-term follow-up of fat injection laryngoplasty for unilateral vocal cord paralysis. *Laryngoscope* 2002;112:1235–1238.
21. Song E, Yeon Kim S, Chun T, Byun HJ, Lee YM. Collagen scaffolds derived from a marine source and their biocompatibility. *Biomaterials* 2006;27: 2951–2961.
22. Addad S, Exposito JY, Faye C, Ricard-Blum S, Lethias C. Isolation, characterization and biological evaluation of jellyfish collagen for use in biomedical applications. *Mar Drugs* 2011;9:967–983.
23. Rastian Z, Pütz S, Wang Y, et al. Type I collagen from jellyfish *Catostylus mosaicus* for biomaterial applications. *ACS Biomater Sci Eng* 2018;4: 2115–2125.
24. Subhan F, Ikram M, Shehzad A, Ghafoor A. Marine collagen: an emerging player in biomedical applications. *J Food Sci Technol* 2015;52:4703–4707.